The Brow Fat Pad Suspension Suture: Safety Profile and Clinical Observations

Kian Eftekhari, M.D., Grace L. Peng, M.D.†, Hannah Landsberger‡, Raymond Douglas, M.D.§ ‖, and Guy G. Massry, M.D. ‖¶*

**Oculoplastic Surgery, Inc., Salt Lake City, Utah; †Department of Otolaryngology, Head and Neck Surgery, Keck School of Medicine, University of Southern California, Los Angeles, California; ‡Tufts University, Medford, Massachusetts; §Division of Oculoplastic Surgery, Department of Ophthalmology, University of Michigan Medical School, Ann Arbor, Michigan; ‖Beverly Hills Ophthalmic Plastic and Reconstructive Surgery, Beverly Hills, California; and ¶Division of Oculoplastic Surgery, Department of Ophthalmology, Keck School of Medicine, University of Southern California, Los Angeles, California, U.S.A.*

Purpose: To evaluate the safety, subjectively assess outcome, and emphasize surgical pearls and critical clinical observations of upper blepharoplasty performed in conjunction with the brow fat pad suspension suture procedure, previously referred to as a "browpexy variant" or "brassiere suture procedure."

Methods: A retrospective 4-year analysis of patients who underwent the brow fat pad suspension suture with upper blepharoplasty was performed. Adjunctive procedures (brow lift and ptosis repair) were categorized. The surgical technique is detailed with emphasis placed on nuances to aid in optimal outcome.

Results: Two hundred and sixteen patients (149 women and 47 men) underwent upper blepharoplasty with the brow fat pad suspension suture. The average patient age is 54 years and follow up is 11 months. One hundred patients had adjudicative brow lift or ptosis repair, and in 20 patients the blepharoplasty was a revision procedure. Subjective assessment of outcome showed excellent aesthetic results with improved brow projection, and enhanced lateral tarsal platform show and eyebrow/eyelid contour. Surgical complications were infrequent and patient satisfaction was high.

Conclusions: This initial large series description of the brow fat pad suspension suture demonstrates that it is a safe adjunct to upper blepharoplasty, which the authors believe subjectively improves overall outcome. Evidence-based quantitative assessments of objective measures of surgical results are currently underway.

(*Ophthal Plast Reconstr Surg* 2016;XX:00–00)

Upper blepharoplasty continues to evolve from what was once a procedure founded on fat excision,[1–4] to one which now gives consideration to native eyelid fat preservation (fat transposition) and autologous fat augmentation (fat grafting).[1,5–17] This paradigm is founded on contemporary thought, which emphasizes recreating a more youthful fullness and contour to the eyelids and periorbital area.[1,5,7,9,12,14–17] Native upper eyelid fat transposition techniques, performed in conjunction with upper blepharoplasty, have been described to preserve eyelid volume,[9–11] fill adjacent periorbital hollows,[12] and act as a tissue substrate to prevent multiple crease formation in Asian patients.[13] One of the authors of this report has been transposing upper eyelid fat flaps for the last 6 years in hopes of minimizing postoperative upper periorbital and sulcus hollows, and improving eyelid contour, volume, and appearance.[9,12] While, to date, no evidence-based reports have documented statistical efficacy in this regard, the procedure has been generally complication free, and anecdotally has yielded excellent results with high patient satisfaction (author experience). Furthermore, while more commonly accepted in lower blepharoplasty[18–22] upper eyelid fat preservation procedures are becoming accepted by oculofacial surgeons as well. This is substantiated by a 2013 survey of members of the American Society of Ophthalmic Plastic and Reconstructive Surgery, which showed that 36% of respondents transpose upper eyelid fat during routine upper blepharoplasty.[23]

In this report, the authors emphasize another fat preservation and repositioning refinement performed as an adjunct to upper blepharoplasty, specifically involving the brow fat pad. The procedure secures the free ends of orbicularis muscle present at the upper and lower edges of the blepharoplasty incision to the superior arcus marginalis periosteum. The union of these structures mechanically elevates and repositions the ptotic brow fat pad to a more youthful location. The authors have noted this minor addition to surgery creates an anterior projection of the brow, a more prominent lateral tarsal platform, and an enhancement of the brow/eyelid contour and transition, all characteristic of a youthful brow and upper eyelid complex. The authors present their 216 patient experience with the procedure, emphasize its safety, and elaborate on surgical pearls and clinical observations they believe are of value.

METHODS

A 4-year retrospective chart review (2012 to 2015) of patients who underwent upper eyelid blepharoplasty surgery with adjunctive brow fat pad suspension suture (BFPSS) by 1 author (G.G.M.) was performed. All patients are from the private practice of this author and all surgeries were performed at an outpatient surgical center where the senior author has privileges. As such, institutional review board

Accepted for publication October 9, 2016.

Supported by royalties from Elsevier and Springer (to G.G.M.) and royalties from Springer (to R.D.).

The authors have no conflicts of interest to disclose.

Supplemental digital content is available for this article. Direct URL citations appear in the printed text and are provided in the HTML and PDF versions of this article on the journal's website (www.op-rs.com.).

Address correspondence and reprint requests to Guy G. Massry, M.D., Beverly Hills Ophthalmic Plastic Surgery, Beverly Hills, California, 150 N. Robertson Blvd. # 314, Beverly Hills, CA 90211. E-mail: gmassry@drmassry.com

DOI: 10.1097/IOP.0000000000000831

approval was not obtained, but the study adhered to the standards of the Declaration of Helsinki. Informed consent was obtained prior to each procedure. After surgery, patients were seen for regular postoperative visits to assess postoperative course, recovery, and complications.

Surgical Technique. All cases were performed under local, conscious sedation or general anesthesia depending on patient preference and associated procedures performed. An eyelid crease and ellipse of skin for excision is marked with the patient supine in the operating room. The demarcated area of the upper eyelid is infiltrated with 2 ml to 3 ml of 1% lidocaine with 1:100,000 epinephrine subcutaneously. A scalpel blade is used to incise the skin and a monopolar electrocautery device is used to perform skin excision. After skin removal, a central transverse incision is made through the exposed nasal orbicularis muscle and orbital septum until fat is identified. The wooden end of a cotton-tip applicator is inserted beneath the muscle and septum for the full width of the eyelid (nasal to temporal) (Fig. 1A). The Q-tip is elevated to tent up the septum and muscle, what the authors refer to as the *orbicularis tent.* This provides a stable backstop, which can be cut down on to divide the muscle/septum while protecting underlying structures such as the levator aponeurosis. The muscle should be divided centrally along its horizontal axis to create equal distribution of muscle above and below the incision. This allows centered fixation of muscle to the arcus marginalis. The brow fat pad is identified just below the orbital orbicularis muscle and above the frontal bone periosteum. A 5-0 chromic suture is used to engage the inferior edge of orbicularis just lateral to the temporal corneal limbus. The chromic suture is passed perpendicularly through the arcus marginalis periosteum (Fig. 1B) and lastly, the upper edge of orbicularis muscle (Fig. 1C). The suture is tied and its end cut short (Fig. 1D). Typically, 1 or 2 additional interrupted sutures are placed in the lateral third of the eyelid. Care is taken to avoid engaging the levator aponeurosis or prolapsed lacrimal gland, if present, with the chromic suture. Functionally, the suture serves to suspend and tuck the brow fat pad superiorly to create a volume-enhancing effect. The skin incision is closed with interrupted and running 6-0 nylon suture at the completion of the procedure (Video, Supplemental Digital Content 1, http://links.lww.com/IOP/A145).

RESULTS

The study cohort consists of 216 patients (432 eyelids) of which 149 are women (69%) and 67 are men (31%). The mean patient age is 54 years (range 34–86 years) and the mean follow up is 11 months (range 3–34 months). A number of patients underwent concurrent procedures to the brows and/or upper eyelids in addition to upper blepharoplasty at the same setting. These included 42 endoscopic brow lifts (22%), 22 direct brow lifts (12%), and 36 ptosis repairs (17%). All brow lifts and 30/36 ptosis repairs were bilateral. One hundred and sixteen patients (54%) had a BFPSS and blepharoplasty without other brow/upper eyelid procedures performed. Twenty of the patients (9%) studied underwent secondary (revision) upper blepharoplasty.

The BFPSS was a well-tolerated upper blepharoplasty adjunct with infrequent complications. Two patients (1%) had erosion of the chromic suture through the skin. In both cases this resoled uneventfully by secondary intention healing within 1 month. One patient had a postoperative notch (<1%) at the location of suture placement (Fig. 2,

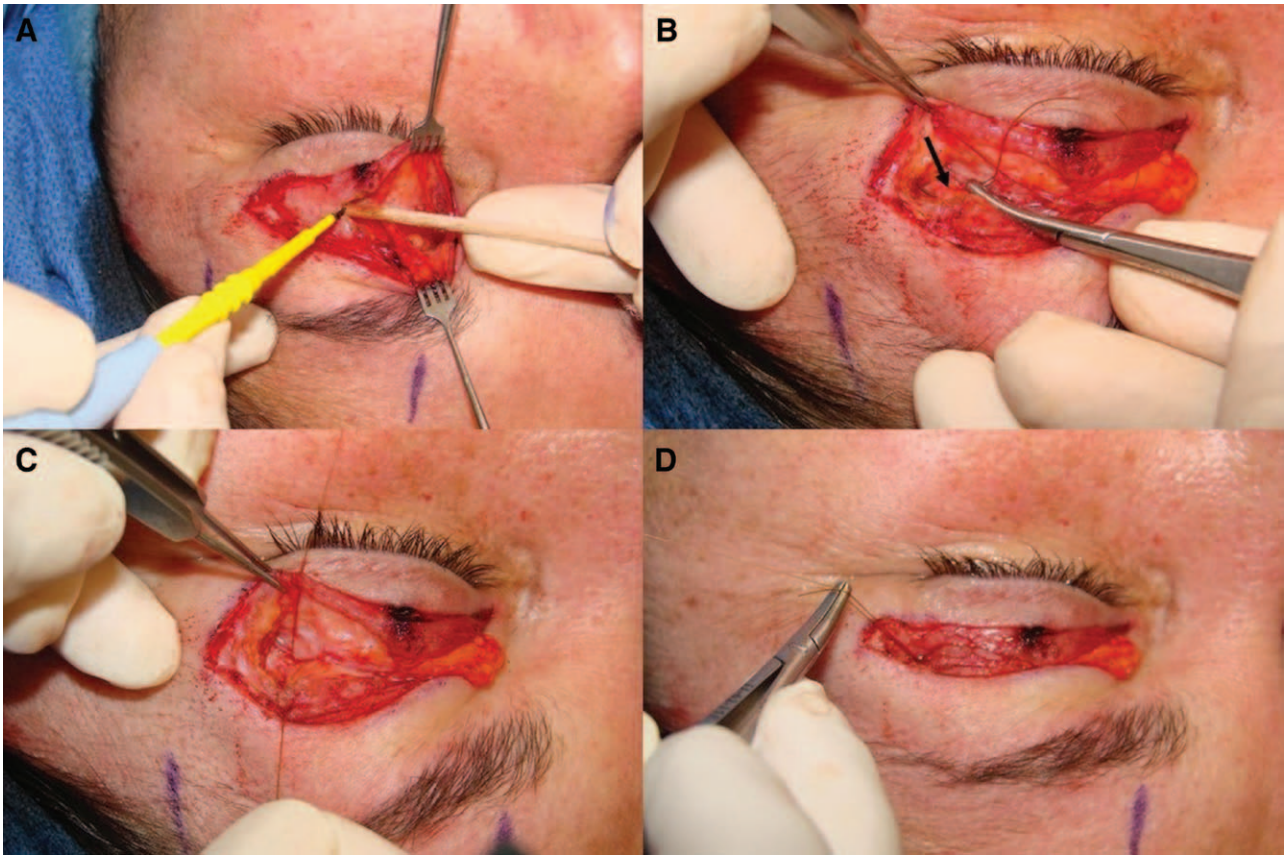

FIG. 1. **A,** The *orbicularis tent*: wooden end of cotton-tip applicator elevates the orbicularis muscle and orbital septum superiorly to act as backstop for division of these tissues. This maneuver protects underlying structures from damage. The muscle is incised centrally along its horizontal plane. **B,** Suture passed through arcus marginalis periosteum (*black arrow*). **C,** Suture shown to engage inferior wound edge orbicularis, arcus marginalis periosteum and superior wound edge periosteum. **D,** Suture tied.

FIG. 2. All patients are before (**left**) and after (**right**) surgery on frontal view. **Top**: Nine months after blepharoplasty with BFPSS. Note symmetric tarsal platform and enhanced brow fullness and brow/eyelid contour. **Second**: One year after temporal endoscopic approach brow lift with blepharoplasty and BFPSS. Note brow fullness and tarsal platform. **Third**: Eight months after isolated upper blepharoplasty and BFPSS. Similar improvement as previous patients. **Bottom**: Note small notch left upper eyelid after surgery.

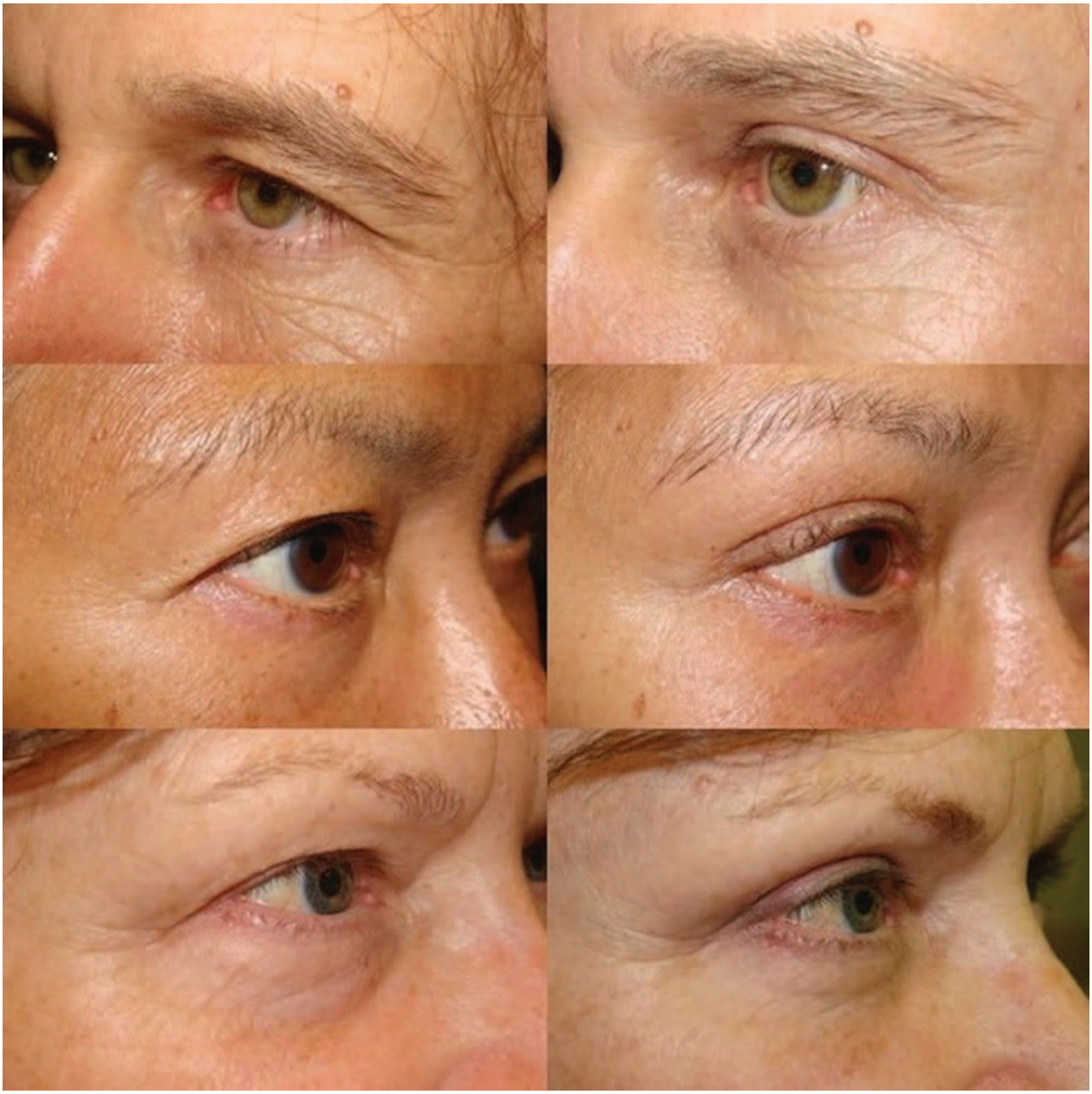

FIG. 3. All patients are before (**left**) and after (**right**) surgery on oblique view. Top 2 patients are 11 and 14 months after temporal endoscopic brow lift, blepharoplasty, and BFPSS. The bottom patient had isolated blepharoplasty and BFPSS (7 months after surgery). In all cases, note improvement in tarsal platform and brow/eyelid contour.

bottom). This was noted by physician and not the patient. Two patients (1%) noted exposure symptoms (dryness and foreign body sensation) for an extended period after surgery. They both had lagophthalmos for greater than 3 months, which resolved on its own with conservative management (lubrication and eyelid squeezing). In each case symptoms and findings were related to orbicularis deficit, and both of these patients were secondary upper blepharoplasties. Two patients (5.5%) out of 36 who had concurrent ptosis repair required ptosis revision with appropriate outcome, and 2 patients (1%) had postoperative lateral upper eyelid induration with inflammatory signs, which resolved with oral steroid use in each case. Two patients (1%), both the ptosis revisions, stated dissatisfaction with their initial surgery, but were satisfied with their final outcome after staged adjustment.

DISCUSSION

In 1997, Dr. Zarem[24,25] introduced his interpretation of the BFPSS as a *browpexy variant* in hopes of elevating the lateral brow, and in his words, *defining the tarsal sulcus (sulcoplasty) and producing a sculpted upper eyelid*. In his technique, after standard skin and fat (nasal and preaponeurotic) excision, he secured the free superior cut edge of orbicularis muscle to the superior arcus marginalis periosteum. His series included 208 patients and he suggested excellent results with few complications. Again his focus was directed at a lateral brow lift and a defined upper sulcus, which was en vogue at the time.

In 2010, Jonathan Hoenig, M.D. (personal communication) described his variation of the BFPSS to one of the authors (G.G.M.), not for the purpose of lifting the brow or sculpting the upper eyelid, but as a means of elevating and supporting the ptotic brow fat pad as an adjunct to fat grafting the brow. He noted the procedure also improved the brow/eyelid contour. Dr. Hoenig, who began adding brow fat pad suspension/elevation to upper blepharoplasty in 1996, further noted that the inferior orbicularis has also been included in the orbicularis/arcus marginalis suspension suture, and that it was Robert Goldberg, MD who coined the name the *brassiere suture*[26] to this maneuver, as it acts as a brassiere to elevate the ptotic brow fat pad.

The current authors' interpretation of the procedure is founded, with minor variation, on Dr. Hoeing's description. While they have not subjectively noted a persistent obvious brow lifting effect as Zarem[24,25] suggested, they agree with Dr. Hoenig that the brow/eyelid transition and contour are improved. The authors perform conservative skin excision, without removal of orbicularis muscle, and only rarely removal of preaponeurotic fat as to preserve upper eyelid and sulcus volume. Their goal is not to deepen the upper sulcus but to naturally recreate the youthful transition of the brow to the upper eyelid. In addition to improved brow/eyelid contour, the authors have also found that the lateral tarsal platform is consistently enhanced. This technique, with these same observations, was formally presented to the American Society of Ophthalmic Plastic and Reconstructive Surgery membership by Robert Goldberg, M.D. at the 2012 American Society of Ophthalmic Plastic and Reconstructive Surgery Fall Meeting in Chicago, Illinois,[27] but to date no large series of patients undergoing this variation of the procedure has been published.

What the author's experience with surgery has shown is as follows. 1) The procedure itself is a technically straightforward addition to standard upper blepharoplasty, which eyelid surgeons should be able to perform easily. 2) Exposure is the same as if the lacrimal gland is to be repositioned (common intervention when needed) in which the temporal retroseptal space is opened. 3) It is critical to assure nonengagement of the levator aponeurosis or lacrimal gland (in close proximity to the lateral superior orbital rim) during suture suspension to the arcus marginalis. 4) The orbicularis muscle should be divided along its central horizontal axis prior to suture placement (Fig. 1A). This allows centered muscle fixation to periostium without undue or unequal tension on the eyelid below and the brow above. 5) The described *orbicularis tent* (see Methods section) facilitates central muscle division and protection of underlying orbital structures (Fig. 1A). 6) While suture suspension of the orbicularis muscle to the orbital rim is more traumatic than standard blepharoplasty surgery, the authors have not noted a substantial increased healing or recovery time compared with similar septal division upper eyelid procedures. 7). A 5-0 chromic suture for fixation is preferred by the authors, as it dissolves (no long-term foreign body), and is proinflammatory, stimulating the formation of a tissue barrier (cicatrix). The authors have noted 2 cases of prolonged (1 month) lateral upper eyelid inflammation/induration, which was steroid responsive. However, this accounted for less than 1% of total cases. A monofilament suture can be exchanged should this be a concern. 8) Typically 2 fixation sutures are placed. However, more can be added depending on surgeon judgment. 9) Fixation sutures are placed lateral to the supraorbital neurovascular bundle. However, not included in this report are 3 patients who had similar sutures placed nasally (care to avoid the supraorbital nerve and blood vessels) to address nasal brow eyelid contour issues in patients with deficits related to previous surgery. These 3 patients had uneventful recovery and were satisfied with their outcome.

This report demonstrates procedure safety; however, clinical observations of outcome are subjectively based on surgeon experience and require further study (see comments below). What the authors have consistently identified are 3 findings which they believe improve aesthetic surgical results. First, the brows appear fuller (less flat) and have more anterior projection (Figs. 2 and 3). Currently this assessment is anecdotal, but the authors are starting a prospective study using 3-dimensional camera technology to assess volumetric changes pre- and post-surgery. Secondly, the authors believe that the lateral tarsal platform is enhanced compared with standard blepharoplasty without the BFPSS. In conjunction with the aforementioned brow projection study, the authors will evaluate this parameter with standardized photographs and measurements comparing patients undergoing blepharoplasty with the BFPSS to patients undergoing standalone blepharoplasty. Finally, because of the 2 findings above, the brow/eyelid transition and contour have consistently been enhanced (more youthful) among the study population. A masked surgeon comparison of outcome, and a patient satisfaction survey, will be added to the prospective study pending to critically evaluate this assumption.

Why this procedure may improve aesthetic surgical outcome, as stated, is a matter of conjecture. The authors believe when the brow fat pad is elevated during blepharoplasty, this, in itself, better defines and enhances the lateral tarsal platform. Also as the brow fat pad is supraplaced with a fixation barrier below, a step-off is created with enhancement or bunching of volume above (Video, Supplemental Digital Content 1, http://links.lww.com/IOP/A145). As the upper lip of the blepharoplasty wound is secured to the arcus marginalis, it may further act as a hammock to the brow fat pad, leading to both improved support, and brow/eyelid transition and contour. Finally, when the cut edges of the divided orbicularis muscle are secured to the superior orbital rim periosteum, a new insertion for the upper orbicularis and origin for the lower orbicularis are created. The forces of orbicularis contraction are now directed to this fixation point, which, by virtue of muscular pull, may further improve tarsal platform and brow fat pad elevation.

When the BFPSS was first added by the authors, the most significant concern was how the manipulation would affect dynamic function of the upper eyelid. While assessment of eyelid closure strength (attempted eyelid opening against forceful eyelid closure by patients) was not routinely performed, only 2 patients (<1%) reported exposure symptoms and manifested lagophthalmos beyond the immediate postoperative period (first 4 weeks). These patients were both upper blepharoplasty revisions, and their findings and symptoms resolved with time. This confirms other's experience with variations of the surgery.[17,24–27] Other complications were equally rare.

An important element of this report was to identify which patients would benefit from addition of the BFPSS. What the authors found is that in most patients, with even early signs of aging of the eyebrow/eyelid complex, the procedure is a useful adjunct. Relative exceptions may include those patients who have had previous blepharoplasty (2 such patients in this report had prolonged lagophthalmos), those undergoing concurrent ptosis repair (2 patents in this series required revision), and possibly those with concurrent inflammatory eyelid disease (i.e., thyroid eyelid disease, etc.). This last potential contraindication is an author assumption and was not identified from the surgical results. The authors excluded these patients as not to potentially stimulate their primary disease process. Finally, the authors subjectively did note that those patients with preoperative volume depleted eyebrows and upper eyelids (typically thin women 50 years old and above) had less anterior brow projection after surgery. These patients still had an improved lateral tarsal platform and brow/eyelid transition,

but may benefit from simultaneous fat transfer to the brows to maximize the overall aesthetic outcome.

In an ongoing effort to improve aesthetic outcomes to both upper and lower cosmetic blepharoplasty, fat preservation and relocation procedures have been added to standard surgery. While not always anatomical or conventional surgical adjuncts, all these procedures have been *subjectively* reported to improve final eyelid and periorbital appearance.[9–12,17–22] Currently, the introduction of 3-dimensional cameras, which can assess soft-tissue volume pre- and postsurgery, may be the best means of statistically verifying these subjective statements. One study, substantiating the efficacy of fat transposition in lower eyelid blepharoplasty using this technology has recently been reported.[28] To the authors' knowledge this is the first report to document such results. Like other volume relocation interventions added to blepharoplasty, this initial large series report of the BFPSS is a surgeon experience description only. With this in mind, the authors have subjectively found the BFPSS, previously called a *Browpexy Variant*, or *Brassiere Suture*, to be a useful aesthetic addition to upper blepharoplasty. A definitive statement of procedure efficacy will follow with the formal prospective evaluation as stated. However, the authors believe the surgical series reported herein does demonstrate procedure safety with few postoperative complications.

REFERENCES

1. Kulbersh JS, Massry GG, Azizzadeh B. Periorbital aesthetic surgery: the evolution of a multidisciplinary surgical subspecialty. In: Massry GG, Murphy MR, Azizzadeh B, eds. *Master Techniques in Blepharoplasty and Periorbital Rejuvenation*. New York: Springer, 2011:3–11.
2. Flowers RS. Upper blepharoplasty by eyelid invagination. Anchor blepharoplasty. *Clin Plast Surg* 1993;20:193–207.
3. Siegel RJ. Essential anatomy for contemporary upper lid blepharoplasty. *Clin Plast Surg* 1993;20:209–12.
4. Siegel RJ. Contemporary upper lid blepharoplasty–tissue invagination. *Clin Plast Surg* 1993;20:239–44; discussion 245.
5. Griffin G, Azizzadeh B, Massry G. Cosmetic upper eyelid blepharoplasty. In: Sclafani A, ed. *Facial Plastic and Reconstructive Surgery*. Philadelphia: Jaypee Brothers, 2015:157–72.
6. Collar RM, Boahene KD, Byrne PJ. Adjunctive fat grafting to the upper lid and brow. *Clin Plast Surg* 2013;40:191–9.
7. Glasgold M, Lam SM, Glasgold R. Volumetric rejuvenation of the periorbital region. *Facial Plast Surg* 2010;26:252–9.
8. Minton TJ, Williams EF. Lipotransfer in the upper third of the face. *Facial Plast Surg* 2010;26:362–8.
9. Massry GG. Nasal fat preservation in upper eyelid blepharoplasty. *Ophthal Plast Reconstr Surg* 2011;27:352–5.
10. Park S, Kim B, Shin Y. Correction of superior sulcus deformity with orbital fat anatomic repositioning and fat graft applied to retro-orbicularis oculi fat for Asian eyelids. *Aesthetic Plast Surg* 2011;35:162–70.
11. Sozer SO, Agullo FJ, Palladino H, et al. Pedicled fat flap to increase lateral fullness in upper blepharoplasty. *Aesthet Surg J* 2010;30:161–5.
12. Yoo DB, Peng GL, Massry GG. Effacing the orbitoglabellar groove with transposed upper eyelid fat. *Ophthal Plast Reconstr Surg* 2013;29:220–4.
13. Lee JH, Kim YD, Woo KI, et al. Preaponeurotic fat advancement in levator recession for treatment of upper eyelid retraction. *Plast Reconstr Surg* 2015;135:680e–90e.
14. Fitzgerald R. Contemporary concepts in brow and eyelid aging. *Clin Plast Surg* 2013;40:21–42.
15. Glasgold RA, Lam SM, Glasgold MJ. Periorbital fat grafting. In: Massry GG, Murphy MR, Azizzadeh B, eds. *Master Techniques in Blepharoplasty and Periorbital Rejuvenation*. New York, NY: Springer, 2011:259–72.
16. Massry GG, Azizzadeh B. Periorbital fat grafting. *Facial Plast Surg* 2013;29:46–57.
17. Briceño CA, Zhang-Nunes SX, Massry GG. Minimally invasive surgical adjuncts to upper blepharoplasty. *Facial Plast Surg Clin North Am* 2015;23:137–51.
18. Goldberg RA. Transconjunctival orbital fat repositioning: transposition of orbital fat pedicles into a subperiosteal pocket. *Plast Reconstr Surg* 2000;105:743–8; discussion 749–51.
19. Massry G, Hartstein M. The lift and fill lower blepharoplasty. *Ophthal Plast Reconstr Surg* 2012;28(3):213–8.
20. Yoo DB, Peng GL, Massry GG. Transconjunctival lower blepharoplasty with fat repositioning: a retrospective comparison of transposing fat to the subperiosteal vs supraperiosteal planes. *JAMA Facial Plast Surg* 2013;15:176–81.
21. Hamra ST. The role of orbital fat preservation in facial aesthetic surgery. A new concept. *Clin Plast Surg* 1996;23:17–28.
22. Massry GG. Comprehensive lower eyelid rejuvenation. *Facial Plast Surg* 2010;26:209–21.
23. Kossler AL, Peng G, Yoo D, et al. Current trends in upper and lower blepharoplasty among ASOPRS members. *Ophthal Plast Reconstr Surg*. In press.
24. Zarem HA, Resnick JI, Carr RM, et al. Browpexy: lateral orbicularis muscle fixation as an adjunct to upper blepharoplasty. *Plast Reconstr Surg* 1997;100:1258–61.
25. Zarem HA. Browpexy. *Aesthet Surg J* 2004;24:368–72.
26. Lee S, Taban M, Strahan R. The utilitarian upper eyelid operation. *Facial Plast Surg* 2010;26:222–31.
27. Goldberg RA. Using a brassiere suture technique to define lateral tarsal platform and eyebrow fat contours. Paper presented at: ASOPRS 2012 Fall Symposium; November 8, 2012; Chicago, IL.
28. Miller TR. Long-term 3-dimensional volume assessment after fat repositioning lower blepharoplasty. *JAMA Facial Plast Surg* 2016;18:108–13.